

PATIENT

Hannah Bowen

SPECIES

Canine

BREED

Chinese Crested

SEX

Female Spayed

AGE

6.26.08

WEIGHT

13.1lbs

INTERPRETED BY

Maggie Machen Lamy,
DVM, DACVIM
(Cardiology)

HOSPITAL NAME

Fullerton Animal
Hospital

REFERRING VET

Dr. Unger

INVOICE

26154

DATE

9.1.22

PRESENTING CLINICAL SIGNS

History: Grade 3/6 right sided heart murmur found on exam when presented for ear infection. History of seizures and ear infections. Multiple growths on body. Corneal edema OS.

-Current medications: Diclofenac and Optimmune OS, Claro AU, Keppra 100mg/mL 1.7mL TID.

-Sedation used: Not required to complete full diagnostic ultrasound.

-Pertinent previous ultrasound results: No previous.

-STAT: Not requested

-Imaging performed by: Andi Parkinson, BS, RDMS.

ECHOCARDIOGRAM FINDINGS

2D, m-mode, color flow and doppler imaging is available. Mild diffuse thickening of mitral valve leaflets with minimal prolapse into the left atrial lumen. Mild eccentric mitral regurgitation with mild left atrial dilation. Normal MR velocity. Normal LV diameter with adequate myocardial function. The tricuspid valve appears mildly thickened with mild to moderate tricuspid regurgitation. Velocity consistent with early pulmonary hypertension. Normal right atrial and ventricular diameter and morphology. The pulmonic and aortic valves are normal in morphology and mobility. Normal pulmonic and aortic outflow velocities with laminar flow. No obvious aortic or pulmonic insufficiency. No pericardial or pleural effusion noted. No obvious cardiac masses.

CARDIAC CHART

CANINE CARDIAC PARAMETERS	MR VMAX (m/s)	TR VMAX (m/s)	LA/AO (Boon method)	LA/AO (Heart Base; Swe)	FS (%)	EF (%)	EPSS (cm)
NORMAL PARAMETER	4.5-5.5	<2.7	1.3	<1.6	28-40	40-100	<0.6
PATIENT	4.8	3.2	NM	1.45	48	82	NM
CANINE CARDIAC PARAMETERS	HR (BPM)	AV VMAX (m/s)	PV MAX (m/s)	BODY WEIGHT (kg)	LA 2D short axis Base view (cm)	LVIDd Avg; 2D and m-mode short axis (cm)	LVIDs Avg; 2D and m-mode short axis (cm)
NORMAL PARAMETER	50-100	0.7-1.7	0.7-1.6	BELOW	BELOW	BELOW	BELOW
PATIENT	170	1.8	1.0	5.9	1.8	2.0	1.1
*Normal chamber parameters expressed as a mean value (SD)				3	1.27 (5.3)	2.46 (2.46)	1.36 (5.5)
BODY WEIGHT DEPENDENT PARAMETERS				5	1.40 (4.5)	2.74 (5.2)	1.60 (4.7)
<i>*Note: All measurements based upon multi-modal images and methods. An average value is reported.</i>				10	1.50 (3.8)	3.27 (3.5)	2.06 (3.1)
				15	1.83 (2.0)	3.71 (2.4)	2.43 (2.1)
				20	2.02 (1.9)	4.14 (2.2)	2.80 (2.0)
				25	2.18 (2.4)	4.48 (2.9)	3.10 (2.5)
				30	2.33 (3.3)	4.83 (3.9)	3.39 (3.4)
				35	2.48 (4.3)	5.17 (5.0)	3.69 (4.5)
				40	2.62 (5.2)	5.48 (6.1)	3.96 (5.4)
				50	2.88 (7.1)	6.07 (8.3)	4.46 (7.4)

Adapted from June Boon, Veterinary Echocardiography, 1998
Rishniw M and Hollis NE, J Vet Intern Med 2000; 14:429-435
Hansson et al, Vet Rad and Ultrasound 2002
Bonagura et al. Echocardiography: principles of interpretation, Vet Clin North Am 15:1177, 1995

INTERPRETATION OF THE FINDINGS & FURTHER RECOMMENDATIONS

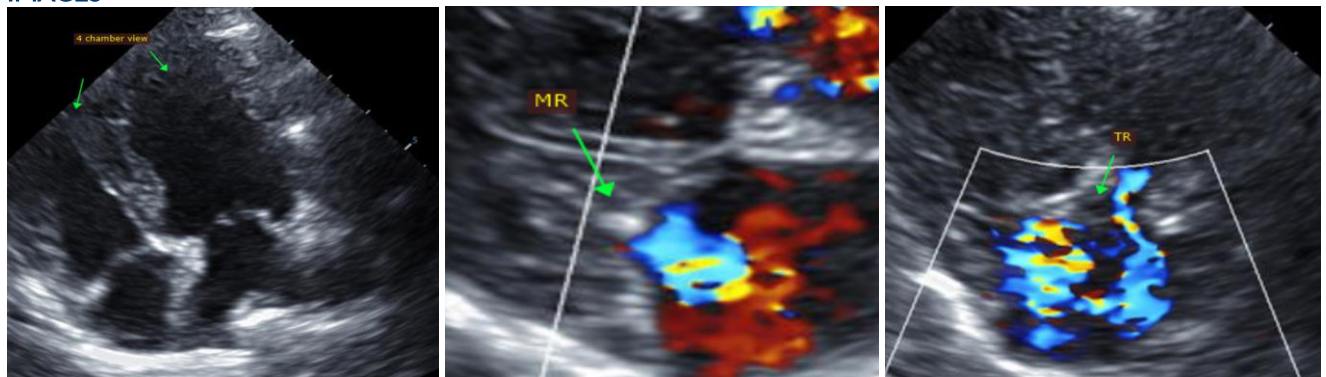
Chronic degenerative valve disease causing mild mitral and mild to moderate tricuspid regurgitation. Lack of significant left atrial enlargement indicates the current risk for complication is low. The TR is quantitatively greater than MR and early pulmonary hypertension is noted, this is of unknown significance in a dog without respiratory symptoms. Simple follow up is advised. No additional issues are noted in this study.

In an asymptomatic dog with no significant left atrial enlargement, no cardiac medications are clearly indicated. Assessment of progression in the future will help predict long term prognosis, which is highly variable at this stage (B1). Omega fatty acid supplementation and mild salt restriction may be of some long-term benefit. Monitor for development of a cough, labored breathing, exercise intolerance or collapse episodes.

Anesthetic risk is considered mild if needed. Cardiac protective drug choices (opioid/benzodiazepine premedication, propofol or alfaxalone induction, isoflurane gas) are recommended. Pre-oxygenate for 5-10 minutes prior to induction. Monitor for arrhythmias, hypotension, and hypoxia both intra and post-operatively and intervene as necessary. Mild IV fluid restriction is recommended to avoid fluid overload. Avoid heart rate stimulating drugs such as atropine unless clinically indicated.

Recommend conservative monitoring with a recheck echocardiogram in 6 months, sooner if any development of clinical signs.

IMAGES



The information and recommendations provided are based on the images presented by the referring veterinarian. No evaluation can be communicated regarding pathology that was not visible in the image/video clips provided.

Thank you for this referral. This report was generated using transcription software, and minor dictation errors may be present. If the clinical or image interpretation does not parallel your findings or if I can be of any further assistance, please contact me.

Maggie Machen Lamy, DVM
Diplomate of the American College of Veterinary Internal Medicine (Cardiology)
info@sonopath.com